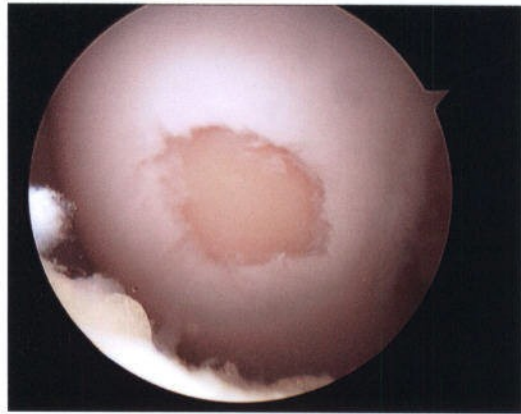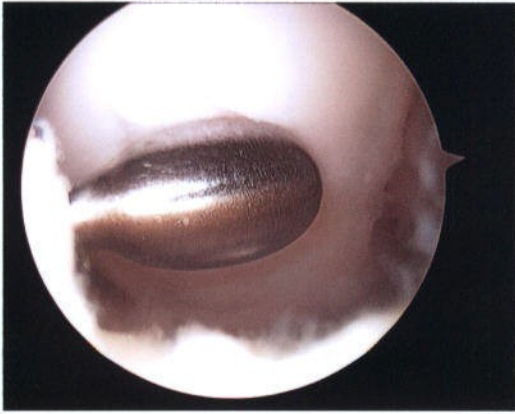
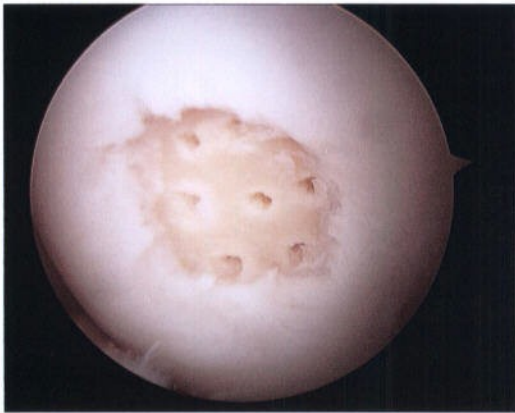


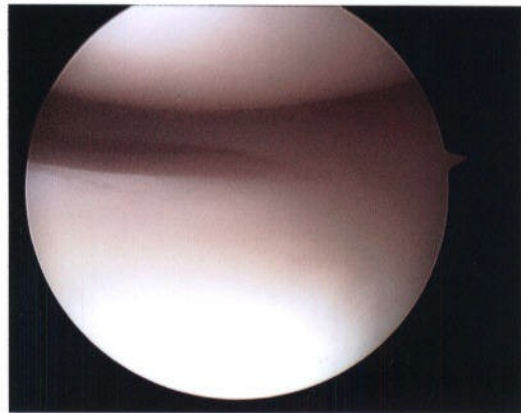
Chondral Defect →



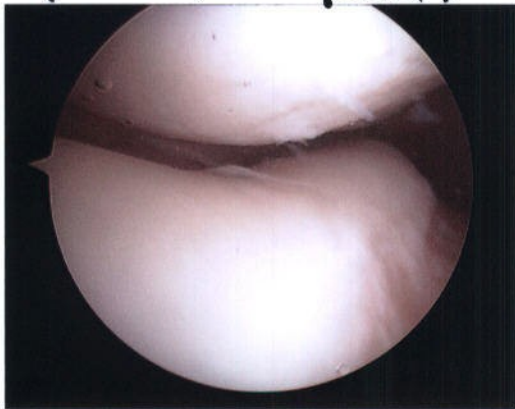
Micro fx



LM



Pat from prox. Lat. portal



MM

