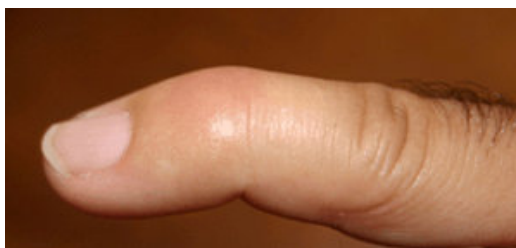

Mallet Finger (Baseball Finger)

A mallet finger is a deformity of a finger caused when a certain tendon (the extensor tendon) is damaged. When a ball or other object strikes the tip of the finger or thumb, the force damages the thin tendon that straightens the finger. The force of the blow may even pull away a piece of bone along with the tendon. The finger or thumb is not able to be straightened. This condition is also known as baseball finger.



Mallet finger.

Symptoms

The finger is usually painful, swollen, and bruised. The fingertip may droop noticeably. Occasionally, blood collects beneath the nail. The nail can even become detached from beneath the skin fold at the base of the nail.

Diagnosis

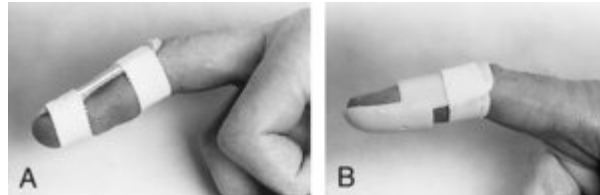
In most cases, the doctor will order X-rays in order to look for a major fracture or malalignment of the joint.

Nonsurgical Treatment

The majority of mallet finger injuries can be treated without surgery. Ice should be applied immediately and the hand should be elevated above the level of the heart. Medical attention should be sought within a week after injury. It is very important to seek immediate attention if there is blood beneath the nail or if the nail is detached. This may be a sign of nail bed laceration or open (compound) fracture.

The doctor may apply a splint to hold the fingertip straight (in extension) until it heals. Most of the time, a splint will be worn full time for eight weeks. Over the next three to four weeks, most patients gradually begin to wear the splint less frequently. Although the finger usually regains an acceptable function and appearance with this treatment plan, many patients may not regain full fingertip extension.

In children, mallet finger injuries may involve the cartilage that controls bone growth. The doctor must carefully evaluate and treat this injury in children, so that the finger does not become stunted or deformed.



Types of splints used to treat mallet finger. A, Dorsal aluminum splint. B, Commercial splint.

Reproduced with permission from Culver JE Jr: Office Mgmt of athletic injuries of the hand and wrist. Instr Course Lect 1989;38:473-482.

Surgical Treatment

Surgical repair may be considered when mallet finger injuries also show signs of large fracture fragments or joint malalignment. In these cases, surgery is done to repair the fracture using pins, pins and wire, or even small screws. Surgery may also be considered if nonsurgical treatment fails.

It is not common to treat a mallet finger surgically if bone fragments or fractures are not present. This is usually reserved for patients who have a very severe deformity or who cannot use their finger properly. Surgical treatment of the damaged tendon can include tightening the stretched tendon tissue, using tendon grafts, or even fusing the joint straight.

An orthopaedic surgeon should be consulted in making the decision to treat this condition surgically.

March 2007



Co-developed w/American Society for Surgery of the Hand

Address:http://orthoinfo.aaos.org/fact/thr_report.cfm&topcategory=Hand&Thread_ID=151

Copyright 2007 American Academy of Orthopaedic Surgeons. www.orthoinfo.org