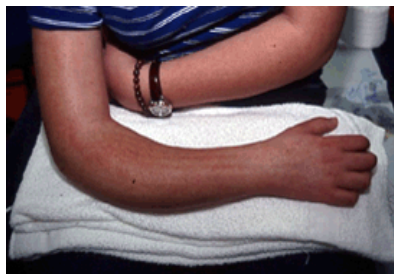


## Forearm Fractures in Children



### Description

Children love to run, hop, skip, jump and tumble. But if they fall onto an outstretched arm, they could break one or both of the bones in the lower arm. Forearm fractures account for 40 to 50 percent of all childhood fractures. Fractures can occur near the wrist at the farthest (distal) end of the bone, in the middle of the forearm, or near the elbow at the top (proximal) end of the bone.

This child's forearm fracture has resulted in a bent appearance of the forearm. It will require a manipulation to restore normal alignment prior to placement in a cast.

The bones of the forearm are the radius and the ulna. If you hold your arm naturally by your side, the ulna is the bone closer to you, and the radius is further away. About three out of four forearm fractures in children involve the wrist-end of the radius.

A child's bones begin to heal much more quickly than an adult's bones. If you suspect a fracture, you should obtain prompt medical attention for the child so that the bones can be set for proper healing.

Types of fractures include:

- **Torus fracture:** Also called a "buckle" fracture. The topmost layer of bone on one side of the bone is compressed, causing the other side to bend away from the growth plate. This is a stable, nondisplaced fracture.
- **Metaphyseal fracture:** The break is across the shaft of the bone and does not affect the growth plate.
- **Greenstick fracture:** The break extends through a portion of the bone, causing it to bend on the other side.
- **Galeazzi fracture:** Affects both lower arm bones; there is usually a displaced fracture in the radius, and a dislocation at the wrist where the radius and ulna come together.
- **Monteggia fracture:** Affects both lower arm bones; there is usually a fracture in the ulna, and the head of the radius is dislocated. This is a very severe injury and requires urgent care.
- **Growth plate fracture:** Also called a physal fracture. The break occurs at or across the growth plate. Usually these fractures affect the growth plate near the wrist on the radius.

The hand, wrist, arm and elbow can all be injured during a fall on an outstretched arm. To determine exactly what injuries occurred, the doctor will probably want to see X-rays of the

elbow and wrist as well as the forearm. The doctor will also test to make sure that the nerves and circulation in the hand and fingers are not affected.

## **Symptoms**

Symptoms of a forearm fracture include:

- Any type of deformity about the elbow, forearm or wrist
- Acute pain
- Tenderness
- Swelling
- An inability to rotate or turn the forearm

## **Treatment Options**

Treatment depends on the type of fracture and the degree of displacement. If the bones do not break through the skin, the physician may be able to push (manipulate) them into proper alignment without surgery.

### **Treatment Options: Surgical**

Surgery to align the bones and secure them in place may be required if:

- The skin is broken.
- The break is unstable.
- Bone segments have been displaced.
- The bones cannot be aligned properly through manipulation alone.
- The bones have already begun to heal at an angle or in an improper position.

After the bones are aligned, the physician may use pins or a cast to hold them in place until they have healed. A stable fracture such as a buckle fracture may require three to four weeks in a cast; a more serious injury such as a Monteggia fracture-dislocation may need to be immobilized for six to ten weeks. If the fracture disrupts the growth plate at the end of the bone, the physician will probably want to watch it carefully for several years to ensure that growth proceeds normally.

June 2004  Reviewed by members of POSNA (Pediatrics Orthopaedic Society of North America)

Address: [http://orthoinfo.aaos.org/fact/thr\\_report.cfm&topcategory=Arm&Thread\\_ID=249](http://orthoinfo.aaos.org/fact/thr_report.cfm&topcategory=Arm&Thread_ID=249)